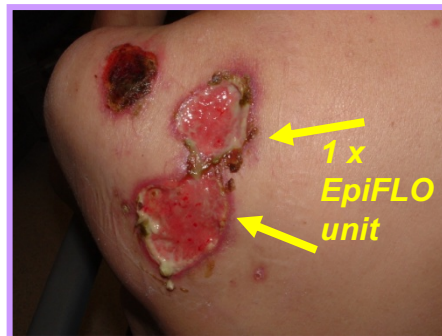
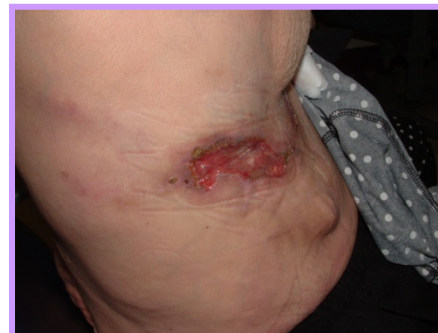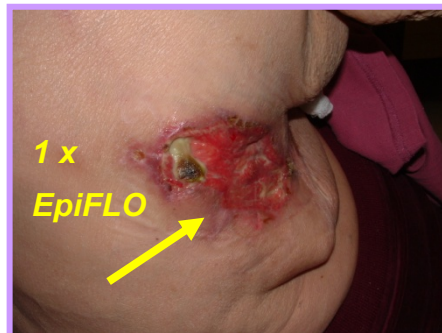

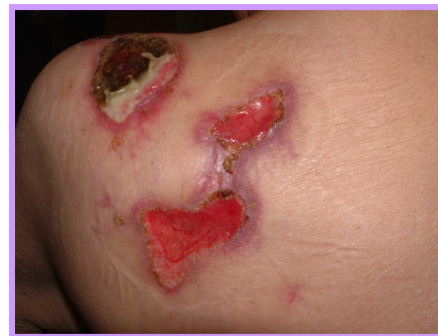
Coumadin Necrosis – Multiple Wounds

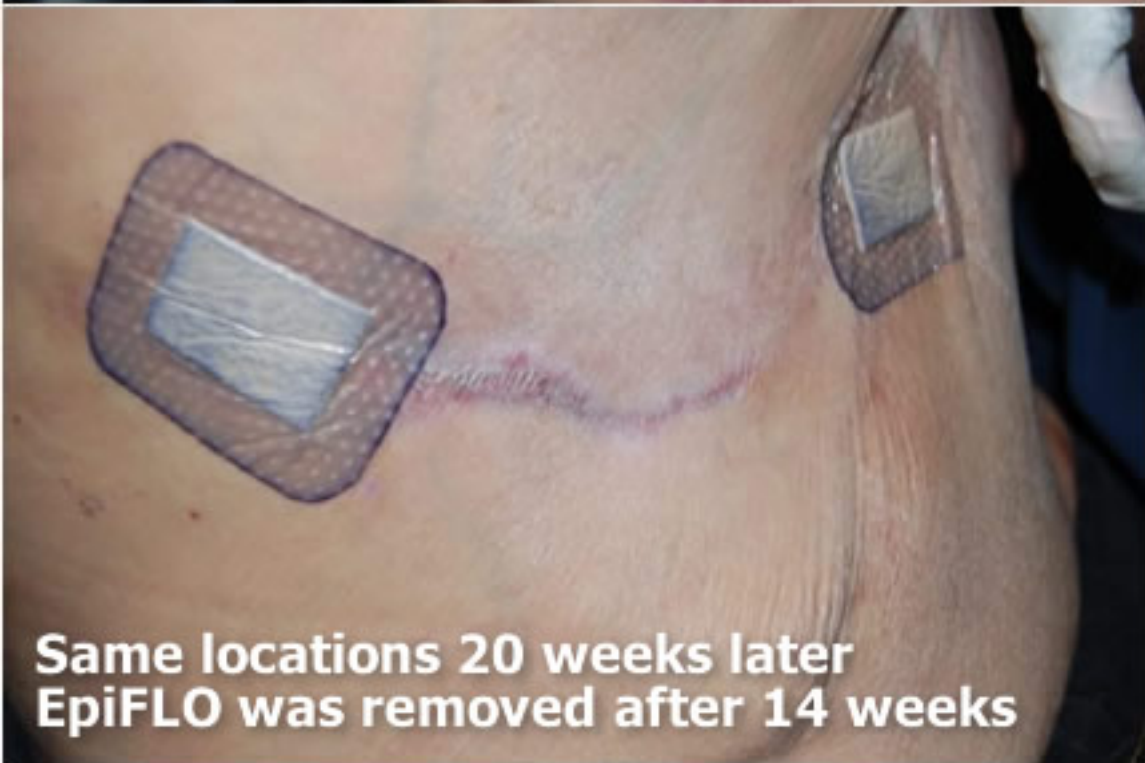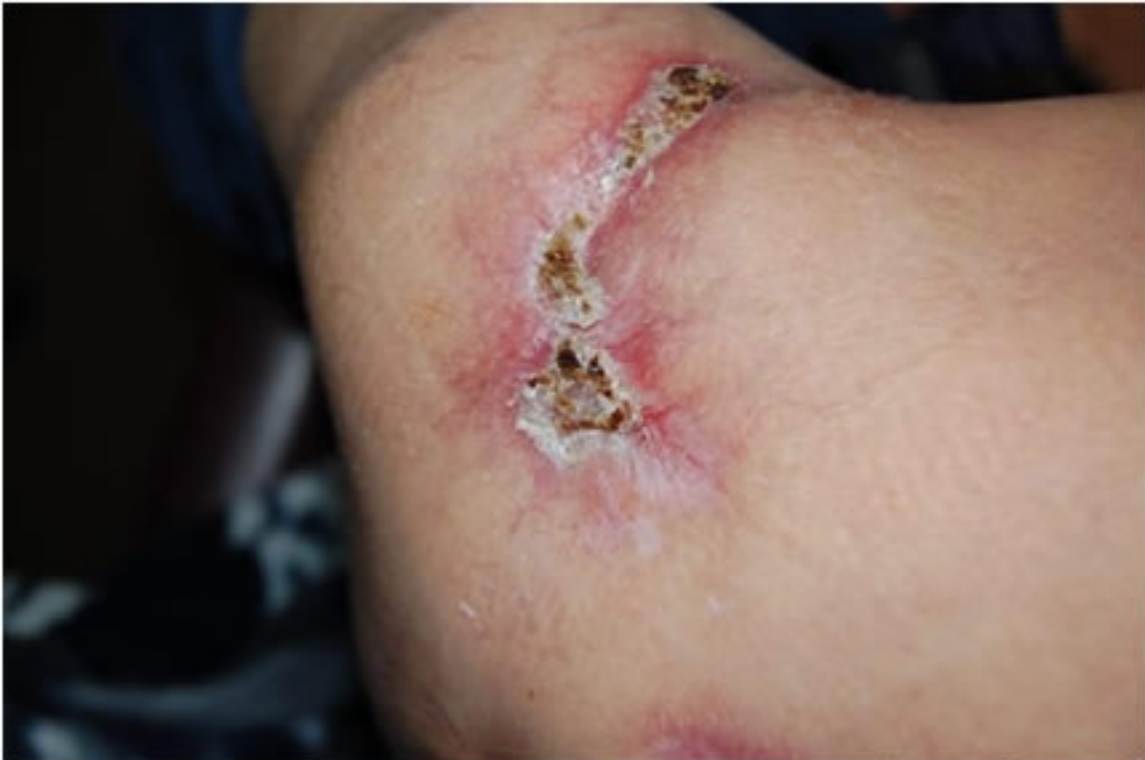62 year old female, coumadin treatment for 27 years; renal failure (dialysis), multiple necrotic wounds appearing and enlarging associated with extreme pain. NPWT attempted but not initiated due to increased pain with vacuum start. Rare wound indication (only hundreds of reports worldwide).



3 weeks
EpiFLO
treatment
(initiated 1
week earlier)



Significant granulation, wound area and depth reduction with complete resolution of associated extreme pain level; ongoing therapy; one EpiFLO used per region



**Same locations 20 weeks later
EpiFLO was removed after 14 weeks**