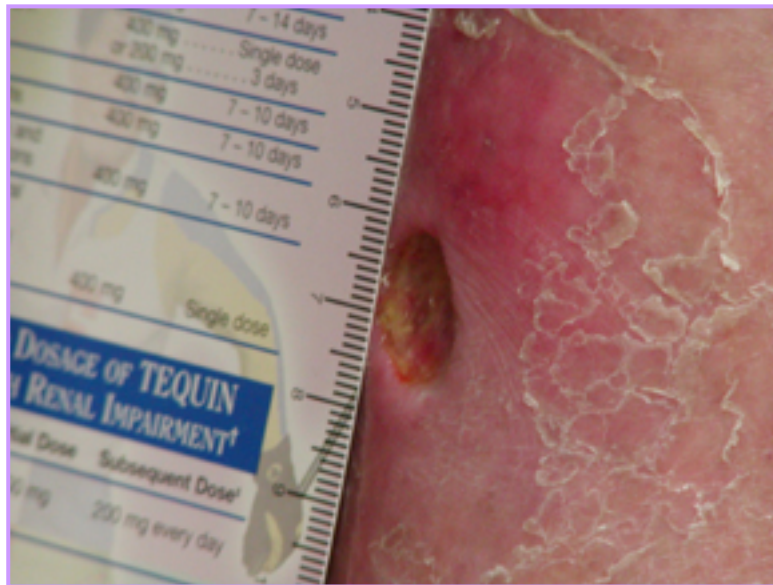


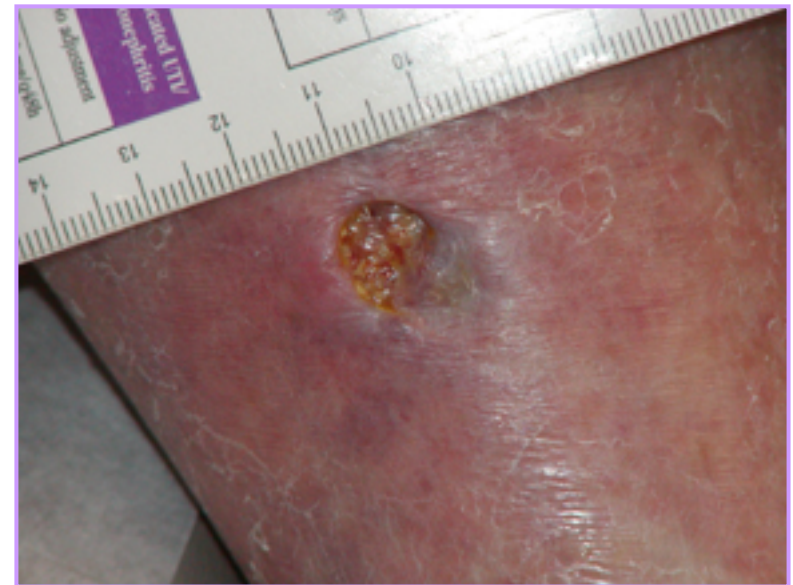
## Non-Healing Lesion / Previous Sarcoma

84 year old female. 9-month history of painful lesion from a previous sarcoma; Prior multi-modal therapy unsuccessful.

**Week 0**



**Week 3 EpiFLO Therapy**



Marked reduction in pain at week 1. By week 3, the lesion had complete epithelialization.