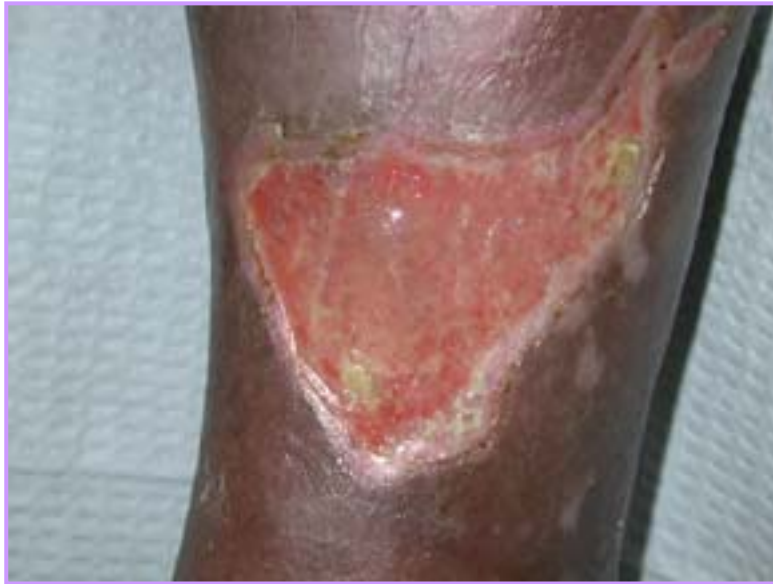

Leg Ulcer

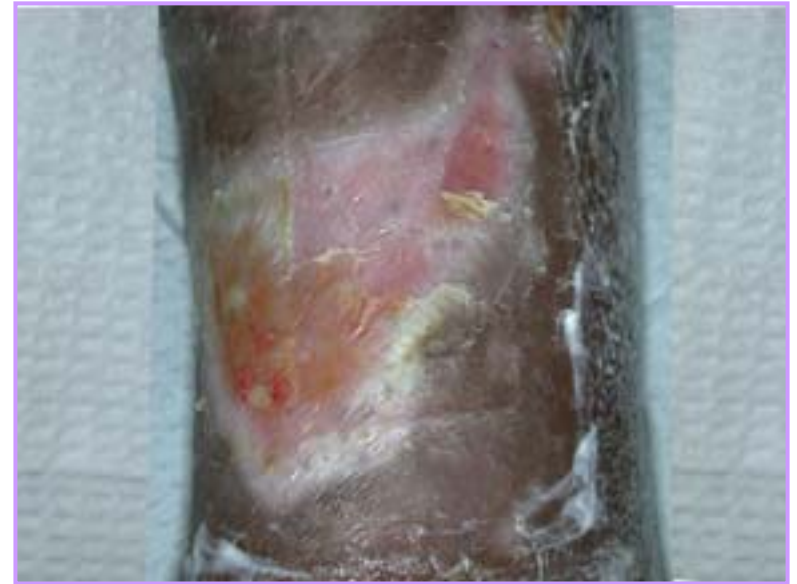
74 year old male. Diabetes with history of renal failure (on dialysis) and moderate leg edema.

Week 0



The wound measured 72 x 80 x 2 mm open, weeping ulcer, that enlarged over a 1-year period on the lower right leg

Week 3 EpiFLO Therapy



Marked reduction in pain. Wound is almost closed