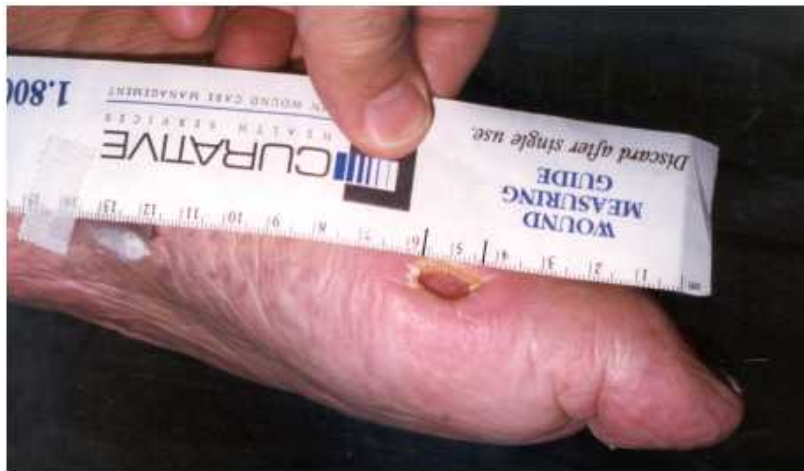


Case: FH103 – Osteomyelitis

Case report: 89 yo WM h/o CHF and recalcitrant wound x 2y; develops osteomyelitis; amputation scheduled, then canceled post TSOT.

Week 0



Week 15

