

The Use of Transdermal Continuous Oxygen Therapy as Adjunctive Treatment to Human Fibroblast Derived Dermal Substitute in Diabetic Foot Ulcers

Howard M. Kimmel, DPM, MBA -Residency Director PM&S 36, Louis Stokes Department of Veterans Affairs, Cleveland, Ohio
Senior Clinical Instructor, Dept. of Surgery Case Western Reserve University School of Medicine, Cleveland, Ohio



Transdermal Oxygen Therapy Unit

Purpose: Oxygen plays a major role in collagen synthesis and angiogenesis. Hypoxia limits redox signaling and disables the function of several growth factors and numerous molecular mechanisms. We wanted to determine to see if using transdermal oxygen therapy could be used as adjunctive treatment on patients with severe peripheral vascular disease. Transdermal Oxygen Therapy 3 milliliters of pure oxygen per hour with ambient humidity at 24 hours per day.

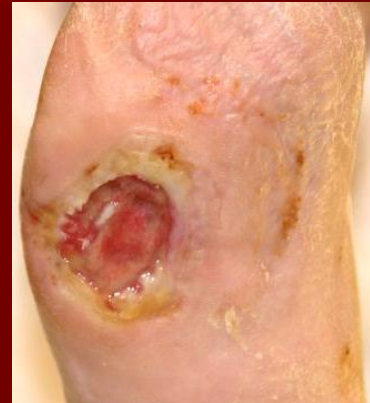Methods: Utilizing an algorithm developed at the Louis Stokes D.V.A., if there is not 50% reduction in wound size in 4 weeks, a Human Fibroblast Derived Dermal Substitute is instituted. If there is not a significant reduction within two weeks of using the Human Fibroblast Derived Dermal Substitute, we instituted adjunctive therapy utilizing Transdermal Continuous Oxygen Therapy. All patients had peripheral vascular disease with ABIs of $x < .7$, elevated HgbA1c's of greater than 7.0, and decreased Albumin of $x < 3.0$.

Results: With the use of Transdermal Continuous Oxygen Therapy as adjunctive treatment, significant angiogenesis was noted. By converting these hypoxic wounds, it is possible that the increase in collagen production laid a lattice for the Human Fibroblast Derived Dermal Substitute. The role of oxygen in stimulating significant growth factors such as PDGF, VEGF, and KGF most likely acted as a catalyst to the growth factors present in the wound and also the Human Fibroblast Derived Dermal Substitute.

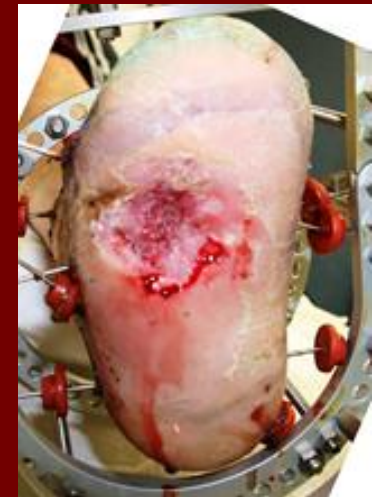Conclusions: Both micro and macro-vascular disease play a significant role in whether a wound is hypoxic or not and can be a causative factor why a wound is not healing. Utilizing Transdermal Continuous Oxygen as adjunctive therapy can possibly "jump start" a wound to take it out of the chronic inflammatory stage into a more acute one and possibly can save a limb or a life!!

References:

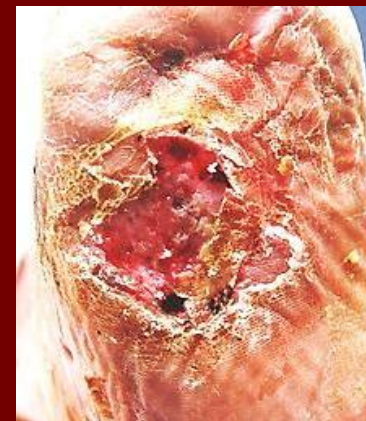
- Coutts, P.; Sibbald, Gary. "Pilot Study to Evaluate the Use of Continuous Topical Oxygen Therapy in the Treatment of Chronic Wound." *American Professional Wound Care Association*, October, 2010.
- Schreml, S.; Szeimies, R.M.; Prantl, L.; Karrer, S.; Landthaler, M.; Babilas, P. "Oxygen in Acute and Chronic Wound Healing" *British Journal of Dermatology*. 2010;163(2):257-268.
- Hirsch, Fred; Berlin, Steven; Holtz, Aliza. "Transdermal Oxygen Delivery to Diabetic Wounds: A Study of 6 Cases." *August, 2008*.
- Said HK, Hijjawi J, Roy N, Mogford J, Mustoe T., "Transdermal sustained-delivery oxygen improves epithelial healing in a rabbit ear wound model." *Arch Surg*. 2005 Oct;140(10):998-1004.



Initial Presentation of Ulcer



Ulcer after 4 weeks of adjunctive treatment



Healed ulcer at 6 weeks