

# Transdermal Sustained Oxygen Therapy (TSOT) heals chronic diabetic ulcers after other advanced therapies failed.

## A retrospective review of 15 patients.

Adir Ludin, M.D.<sup>1</sup>, Claire Wilson, RN, BSN, ET, CWCN, DAPWCA<sup>2</sup>

<sup>1</sup>Department of Radiation Oncology, VA Medical Center, Cleveland, OH; <sup>2</sup>Ogenix Corporation, Beachwood, OH.



### Introduction

Diabetic foot ulcers are estimated to affect approximately 15% of all diabetic individuals during their lifetimes.<sup>1</sup>

They cause patients considerable discomfort, pain, and reduction in quality of life; they are also expensive to treat.

### Materials

We used a disposable device that weighs 2 ounces and measures 2x1x1.5 inches. The oxygen is delivered at a rate of 3 ml/hr for 7 days, via a 5 Fr. cannula to the wound, covered by an occlusive dressing. The device has been cleared by the FDA for a broad list of indications.

### Discussion - The Role of Oxygen in Wound Healing

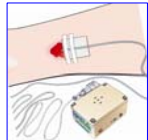- The amount of deposited collagen is directly proportional to the measured tissue oxygen tensions.<sup>2</sup>
- The bactericidal activity of granulocytes depends on high amounts of oxidants. The adequacy of oxidative killing is directly proportional to local oxygen tensions.<sup>3</sup>
- Oxidative and antibiotic killing of bacteria are independent mechanisms and are additive in wounds.
- Angiogenesis occurs more rapidly in well oxygenated tissue.
- Tensile strength of incisional wounds increases with increasing oxygen concentration with optimal wound healing achieved at 100% oxygen at 1 atmospheric pressure.<sup>4</sup>
- Epithelialization depends on oxygen tension.<sup>4</sup>

### Device Application

#### Use of TSOT for treatment of diabetic ulcers

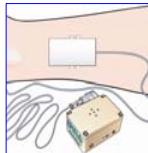
##### Step One:

A gauze bridge is used to protect the peri-wound area. Position the tip of the cannula in the middle of the wound bed. Secure cannula with paper tape.



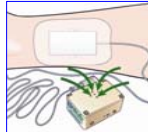
##### Step Two:

Cover the wound and tip of the cannula with a primary moisture absorbent dressing.



##### Step Three:

Use a transparent film as the secondary dressing. Ensure the dressing margins are completely sealed to the skin.



### Mechanism

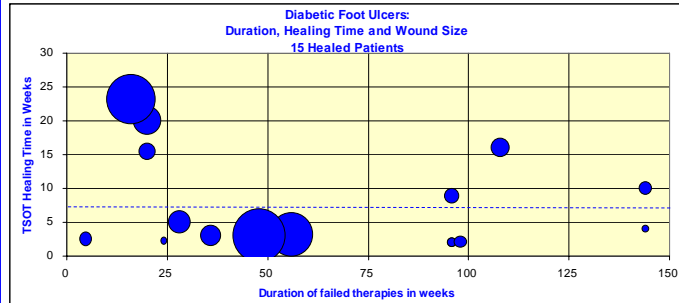
The effect of Transdermal Sustained Oxygen Therapy on wounds was studied on the ischemic rabbit ear model.<sup>5</sup>

#### Results:

Increased epithelial coverage by 91% at 5 days and 156% at 8 days  
Improved granulation tissue formation and provisional matrix deposition.

### Wound Data

- Age of patients 51 to 77 years
- Average age 68 years
- Age of wounds: 8-144 weeks
- Mean age of wounds: 63 weeks
- Size of wounds: 0.2-58 cm<sup>2</sup>
- Mean size of wounds: 14 cm<sup>2</sup>



Wound size cm<sup>2</sup> 50 25 10 Average time to heal 7 weeks

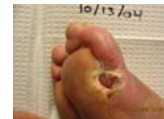### Results

The wounds were healed at 7 weeks on average. Pain resolved within 2 weeks of initiation of therapy. No complications were reported.

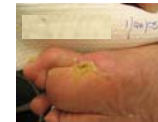### Conclusion

Transdermal Sustained Oxygen Therapy (TSOT) enhances healing and promotes epithelialization. Healing of chronic wounds has significance to the general population and impact on healthcare facilities and costs. Large, prospective trials are needed to document the effects of TSOT.

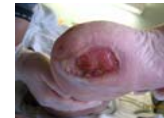**Case #1** 77 y old. Diabetic wound on right foot with osteomyelitis. Age of wound 20 weeks. 2.5cm x 2.5 cm x 1.0cm size. Pain issues: neuropathic. Amputation scheduled with vascular surgeon.



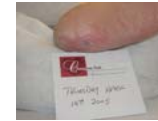Closed at 15 weeks



**Case #2** 51 y old. Diabetic wound on left heel. Age of wound 20 weeks. 3.0cm x 5.5cm x 0.25cm size. Pain issues: 10/10 on day 0. Pain free at day 2. Amputation imminent.



Closed at 20 weeks



**Case #3** 76 y old. Diabetic wound on plantar surface of left foot. Age of wound 132 weeks. 1.0 cm x 0.5 cm x 0.4 cm size. Pain issues: neuropathic. Risk of amputation: The podiatrist would not give up!



Closed at 3 weeks



### References

- 1 Palumbo PJ, Melton LJ. Peripheral vascular disease and diabetes. In: Harris MI, Hamman RF, editors. Diabetes in America. Washington, DC: U.S. Government Printing Office; NIH publication no. 85-1468; 1985. p. XV 1-21.
- 2 Tandara A and Mustoe T. Oxygen in wound healing – More than a nutrient. World J Surg 28, 294-300, 2004.
- 3 Clano Paul. Advances in the treatment of the diabetic foot: Is there a role for adjunctive hyperbaric oxygen therapy? Wound Rep Reg 2004;12:2-10
- 4 Ninkoski J. Current concepts of the role of Oxygen in wound healing. Annales Chirurgiae et Gynaecologiae 90 Suppl 2:15-9-11, 2001
- 5 Said HK, Higjawi J, Roy N, Mogford J, Mustoe T. Transdermal sustained-delivery oxygen improves epithelial healing in a rabbit ear wound model. Arch Surg 2006;141(10):998-1004.